JOURNAL OF CLINICAL MEDICINE OF KAZAKHSTAN (E-ISSN 2313-1519)
Original Article DOI: https://doi.org/10.23950/jcmk/11043

Evaluation of the effectiveness of non-invasive instrumental diagnostics in the detection of urolithiasis

Reza Fatkhi, Shora Seidinov

Khoja Akhmet Yassawi International Kazakh-Turkish University, Turkistan, Republic of Kazakhstan

Received: 2021-04-27.
Accepted: 2021-06-13

J Clin Med Kaz 2021; 18(4):58-63

Corresponding author:
Reza Fatkhi.
Email: reza.fatkhi@bk.ru

Abstract

Aim: To assess the effectiveness of non-invasive instrumental diagnostics in the detection of urolithiasis, particularly ultrasonography and computed tomography.

Materials and methods: Ultrasonic diagnosis and computed tomography were performed in 78 and 104 patients, respectively. All patients were diagnosed with urolithiasis of different localization. The study was conducted at the Regional Clinical Hospital of Shymkent city for the period 2017-2018. Also, a study of medical documentation and questionary observations were carried out with subsequent statistical processing.

Results: Various calculi were detected in 27 patients using ultrasonography in addition to the other symptoms of urolithiasis: change in the size and configuration of the kidney, the expansion of the pyelocaliceal complex and compaction of the parenchyma of the affected organ. 48.3% of the total number of stones was found on the right kidney, the remaining stones (51.7%) were found in the left kidney. In the upper, middle and lower groups of pyramids there were detected 10.7%, 32.2% and 28.6% of calculi, respectively. In the pelvis of the right and left kidneys, 17.8% and 10% calculi were found, respectively, and in the calyx-pelvis complex of the right (10.7%) and left (20%) kidneys.

Conclusion: The analysis of the effectiveness of the ultrasound and computed tomography was demonstrated that the sensitivity, specificity and accuracy of computed tomography were higher than these parameters of ultrasound, which was also confirmed by the results of computation of the receiver operating characteristic curve and the area under this curve.

Key words: ultrasound, computed tomography, urinary lithiasis, kidney stones

Introduction

Urolithiasis is a widespread pathology of the organs of the urinary system (OUS). The development of new methods for early non-invasive diagnosis of urolithiasis is rapidly developing every day. However, in the literature, there are little data available on the effectiveness of existing clinical methods for the detection of stones of the kidney and lower urinary tract. This paper provides the assessment of finding calculi in the OUS using ultrasound and computed tomography and evaluates the quality of the use of visualisation methods of diagnostics in the detection of urolithiasis.

With the development of modern methods of instrumental diagnostics in medicine in general, as well as in urology in particular, the relevance of studying the effectiveness of one or another instrumental method is one of the main questions for most scientists. Identification of metabolic risk factors and correct interpretation of the data obtained has an important role in the treatment of patients and prevents recurrence of the disease [1]. According to the Recommendations of the European Association of Urology, the classification of urolithiasis is based on the type of stones and the severity of the symptoms of the disease and includes a simplified overview of the principle of stone analysis [2]. Researchers emphasize the role of metabolic examination in patients with high stone formation, especially in children [3, 4].

Ultrasound diagnostics plays a vital role in detecting calculus, determining its localization, size and developed complications [3]. This imaging technique uses high-frequency sound waves, an echo of which is reflected back from dense structures, including calculi. Currently,

real-time ultrasound is used as the first-choice imaging method for urolithiasis during pregnancy, since it is not associated with such risks of radiation exposure as teratogenicity, mutagenicity and carcinogenicity to the foetus [5]. It is also the instrument of choice for imaging kidney stones in children. The use of colour ultrasound and power dopplerometry makes it possible to assess the violation of uro- and hemodynamics. Important features of this method are its non-invasiveness, absence of radiation exposure and the development of allergic reactions. The use of ultrasonography makes it indispensable for studying the dynamics of the early and late postoperative period.

On the other hand, computed tomography (CT) uses an X-ray beam that rotates around the patient's body to produce a series of images, followed by three-dimensional reconstruction of the pattern. Non-contrast spiral computed tomography is becoming more common due to its speed, accuracy and efficiency in detecting all types of stones in any location, and without the need for a contrast agent. Moreover, there are many studies in the literature about the high sensitivity and specificity of CT, which can reach 96-100% [6, 7].

CT provides information on the composition of the stone, the degree of obstruction, the anatomy and physiology of the kidneys, as well as any non-urological sources of pain such as appendicitis, pancreatitis, and gynaecological disorders [8]. The disadvantages of this method include a large amount of ionizing radiation, which limits its use mainly in pregnant women and children. To address this problem, low-dose CT and dual-energy computed tomography (DECT) CT have recently been introduced. When imaging stones using DECT, calculi are displayed in different colours depending on their type [7-9].

Materials and methods

The source of passport, social and demographic information during the research work was such materials as state registration of patients with urolithiasis ICD - N20-N21 summary reporting form №12, medical outpatient cards of patients - registration form №025 / at the Ministry of Health of the Republic of Kazakhstan. In addition, a questionnaire survey was conducted of 78 respondents with urolithiasis who underwent ultrasound research.

The questionnaire consists of 10 standard questions, including passport data, age, permanent residence, social and marital status. Separate questions about the state of urolithiasis in patients have also included: the clinical manifestation of the disease, the availability of surgical treatment, the presence of calculi and medical support for patients after diagnosis. The presence of bad habits and aggravating status (CVS pathology, infectious) were also indicated in the list of questions. The survey of respondents was carried out voluntarily, after receiving the results of ultrasound and CT.

Table 1 demonstrates that out of 78 patients, who underwent ultrasound, 60.2% are male and 39.8% are female.

Table 1 Volumes of ultrasound examination of patients with urolithiasis, total and by gender

Examination period	Number of ultrasound examinations		
	male	female	Total
2017	21	14	35
2018	26	17	43
Total	47	31	78

Table 2 Geographic characteristics of the respondents (data from the questionnaire survey)

Examination period	Number of ultrasound examinations		
	urban residents	village residents	total
2017	19	16	35
2018	21	22	43
Total	40	38	78

Table 3 Indicator of age characteristics of patients with urolithiasis who underwent ultrasound

Examination period	Number of patients studied (abs. number /%)					Total
	18-23 y.o.	24-35 y.o.	36-49 y.o.	50-59 y.o.	60 y.o. and older	
2017	4 (11.4%)	7 (20%)	8 (22.9%)	12 (34.3%)	4 (11.4%)	35
2018	7 (16.3%)	10 (23.3%)	12(27.9%)	9 (20.9%)	5 (11.6%)	43
Total	11 (14.1%)	17 (21.8%)	20 (25.6%)	21 (26.9%)	9 (11.6%)	78

The total number of patients in 2018 was 8 people more. Due to the availability of ultrasound studies, both patients from the city and residents of rural areas were equally diagnosed with urolithiasis using this diagnostic technique (Table 2). About half of the patients who underwent ultrasound diagnostics are respondents aged 36 to 59 years, as can be seen from Table 3.

78 and 104 patients underwent ultrasound and the recommended gold standard CT examinations without contrast enhancement, respectively. All patients were diagnosed with urolithiasis of different localization. Patients of the Turkestan region underwent examinations at the Regional Clinical Hospital of Shymkent city for the period 2017-2018. In addition, a study of medical documentation was carried out with subsequent statistical processing.

Ultrasound diagnostics using the B-scan mode [14, 15], which is a set of A-scans passing along the tissue surface, plays a crucial role in identifying stones, determining their location, size and developed complications. The A-scan comes from reflected sound waves and its time delay function (depth) [16]. In addition to them, they also distinguish between C-scan and D-scan, which are necessary for three-dimensional visualization of organs and their systems, as well as TD-scan, which is a set of A-scans passing through the same location.

Voluson ™ E8 / E8 Expert ultrasound system was used, which is a professional versatile real-time ultrasound scanning system. 3D / 4D volumetric scanning technology provides system users with new possibilities, the size of the contact surface is 18 × 24 mm, and the frequency of sound waves is 1.5-3.6 MHz. The digital setting allows optimal use of all the above scanning modes and types of probes over the entire operating frequency range.

Scans of the kidneys, bladder and ureter were obtained using multislice computed tomography (MSCT) - DifinitionAS 64. The device provides thin sections of tissue in high resolution and quality. Section thickness varied within 0.6-3 mm. Also, a distinguishing feature of the device is its exposure time, for each

slice it took about 10 milliseconds. The high scanning speed is not only beneficial for the patient but also prevents and reduces the number of artefacts, which is useful for the interpretation of the results.

Inspection and calibration of technologies were carried out before using the instrumentation. Artefacts and shadows can often be detected without preliminary assessment of the diagnostic tool function, which can often be interpreted as pathology [10, 11]; or due to the lack of constant calibration and "washed-out" images, important symptoms can be missed in both US and CT studies [12, 13].

The images were also processed using the instrumentation software and manual test processing of the obtained randomized TIFF images was performed. This was intended to assess the serviceability and reliability of both the machine itself and the firmware of the equipment. Examples of ultrasound and tomographic scans are shown in Figures 1 and 2, respectively.

Results

Figure 1 illustrates an example of an ultrasound scan of the kidney of a patient with urolithiasis, where it is possible to determine the localization of the stone on the left kidney. A hyperechoic calculus 10 × 5 mm in size has a rounded shape. The result of the CT scan is demonstrated in Figure 2, where, in addition to the kidney, the ureter was also examined. In this patient with urolithiasis, the tomogram shows the localization of the calculus of the inferior renal calyx. Dense and clearly contoured rounded calculus measures 4 × 1 mm in size.

Figure 1 -Ultrasound image of a kidney of a patient with urolithiasis. In the structure of the tissue, pyramids and pelvis, inflammatory and degenerative changes are noticeable, as well as hyperechoic contents on the left: a rounded calculus, 10 × 5 mm in size

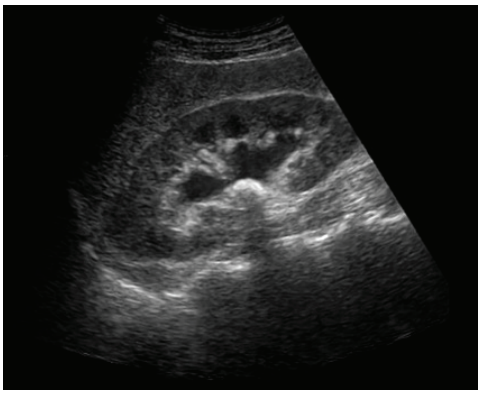

Figure 2 - CT scan of the kidney and ureter. The symptoms of urolithiasis are visualized: heterogeneity of the shape and pattern of the kidney, localization of round stones in the lower renal calyx and middle third of the ureter measuring 4 × 1 mm (both indicated by arrows)

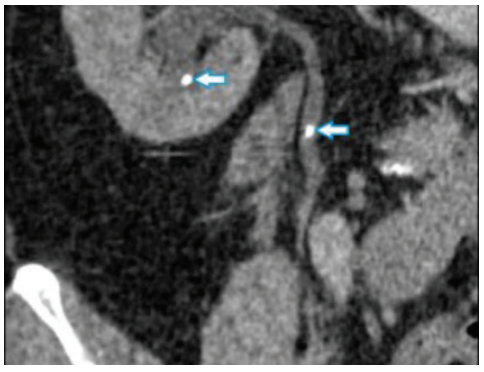

Table 4 Quantitative indicator of the examined organs of the urinary system using CT

Examination period	The number of examined organs of the urinary system			
	kidneys	ureter	bladder	Total
2017	13	12	10	35
2018	14	14	15	43
Total	27	26	25	78

Table 5 Indicator of localization of calculi in the kidneys, total - 58

Localization of calculi	The number of stones (abs. num. / %)	
Upper group of pyramids	3 (10.7%)	2 (6.7%)
Middle group of pyramids	9 (32.2%)	10 (33.3%)
Lower group pyramids	8 (28.6%)	9 (30%)
Pelvis	5 (17.8%)	3 (10%)
Pyelocaliceal complex	3 (10.7%)	6 (20%)
Total	28 (48.3%)	30 (51.7%)

After ensuring the quality of the images and the functionality of the ultrasound machine and computed tomography, as well as their ability to visualize stones, further studies were carried out on the localization and morphology (shape and size) of calculi in the OUS, as well as their quantitative characteristics. In addition, the analysis was conducted of the diagnostic effectiveness of the instrumental research methods in identifying calculi in urolithiasis.

Of 78 patients with urolithiasis, kidney stones were found in 27 patients (Table 4). The number of calculi of various calibre was 58. Ultrasound criteria for the presence of kidney stones were the presence of an echo-positive formation with an acoustic path behind the calculus. In these patients, in addition to the presence of stones, symptoms such as a change in the size and configuration of the affected kidney and expansion of the pyelocaliceal complex, as well as a change in the size of the affected kidney and compaction of the parenchyma of the affected organ were revealed.

During the observations, there were found the number of calculi on the sides of the kidney lesion when calculating the lesion side prevalence. So, in 11 patients, stones were in the right kidney, whereas in 8 patients stones were detected in the left kidney. However, these were only unilateral renal lesions; in the remaining eight patients, calculi were diagnosed in both kidneys. Only one patient had a case of a single kidney who underwent a nephrectomy at the age of 20.

Out of only 58 stones found, right-sided stones were found in 28 patients, which is 48.3% of the total number of stones (Table 5). The remaining stones (30 or 51.7%) were found in the left kidney. At the same time, in the upper group of pyramids in the right kidney, there were 3 (10.7%) calculi, 2 (6.7%) calculi in the left kidney. In the middle group of pyramids, 9 (32.2%) and 10 (33.3%) stones were found in the right and left kidneys, respectively. In the lower group of pyramids of the right and left kidneys, 8 (28.6%) and 9 (30%) calculi were found, respectively. In the pelvis of the right and left kidneys, 5 (17.8%) and 3 (10%) calculi were found and, respectively, in the calyx-pelvis complex of the right and left kidneys - 3 (10.7%) and 6 (20%).

In addition to ranking according to localization, for the studied 2 years, a total of 25 (32.1%) cases were diagnosed with urolithiasis with localization in the bladder (Figure 3), while 26 (33.3%) cases were detected in the ureters (Figure 2). Registration of urolithiasis has an uneven distribution, so in 2017, of total urolithiasis, 35 cases took place, 13 (37.1%)

Figure 3 - CT examination of the bladder of a patient with urolithiasis. The image shows a bladder filled with contrasted urine and stones (indicated by arrows)

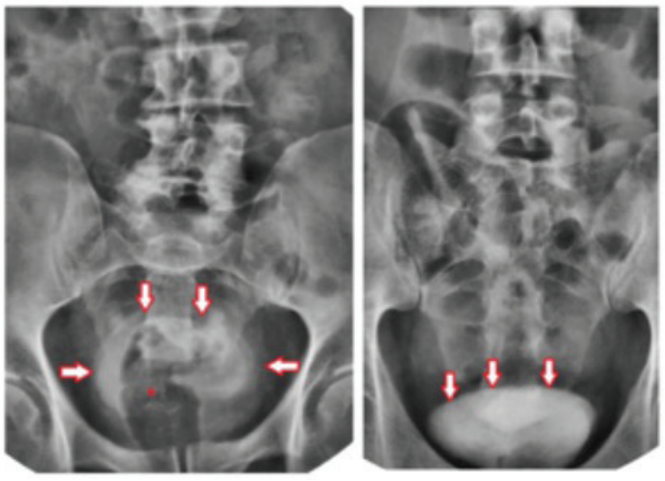

cases were registered with calculi localization in the kidneys, 12 (34.2%) cases were localized in the ureter. 28.6% of cases with localization of calculi in the bladder - 10. In 2018, of the total registered urolithiasis - 43 cases, there was a registration of urolithiasis with localization of calculi in the bladder - 15 (34.8%) cases, urolithiasis with localization of calculi in the kidneys - 14 (32.6%) cases and urolithiasis.

In addition to localization, analysis of the size of calculi in the kidneys was also carried out. According to the diameter of the stones, a classification was made into 4 groups: 1-4 mm, 5-11 mm, 12-20 mm, 21 mm and larger. The method of instrumental research was also considered. Thus, the total number of calculi on ultrasound was 53, while 58 stones were diagnosed using CT (see above). Despite the high resolution of CT, small stones 1-4 mm in size in most cases were detected on ultrasound: 13 versus 4 on CT.

However, the detection of medium stones with a diameter of 5-11 mm and 12-20 mm prevailed during tomography: 19 and 25, respectively. Ultrasound diagnostics revealed calculi of these sizes in the amount of 12 (5-11 mm) and 18 (12-20 mm). An equal ratio of detection of stones with a diameter of 21 mm or more was detected by both ultrasound and CT and was equal to ten (Table 6).

Table 6 A quantitative indicator of the size of the calculus in the kidneys

Sizes of stones	Number of stones in the kidney	
	Ultrasound (abs. num. /%)	CT (abs. num. /%)
1-4 mm	13 (24.6%)	4 (6.9%)
5-11 mm	12 (22.6%)	19 (32.7%)
12-20 mm	18 (33.9%)	25 (43.1%)
21 mm and larger	10 (18.9%)	10 (17.3%)
Total	53	58

It should be noted that the use of the ultrasound research method has certain advantages since it does not require special preparation of the patient for the study, and in our studies, real visualization of calculi 1-4 mm in size was 3.2 times larger than the US (13 cases), compared to CT (4 cases). However, with CT diagnostics, the possibility of real visualization of calculi with a size of 5-11 mm was 1.5 times more and amounted to 19 cases with CT compared to ultrasound - 12 cases.

Similarly, visualization of calculi with a size of 2-20 mm was greater and amounted to 25 cases in CT diagnosis compared to ultrasound in 18 cases. Possibilities of visualization of calculi with a size of 20 mm or more, both diagnostic methods had the same possibility for 10 cases each. The use of the CT method made it possible to identify all calculi with sizes over 4 mm, while ultrasound diagnosed a greater number of them when the size of the calculus did not exceed the specified value: for example, by ultrasound, 9 additional calculi with sizes from 1 to 4 mm were detected, which were not detected by CT-diagnostics.

The analysis of the effectiveness of the ultrasound and CT methods used was carried out using the MATLAB application package version R2017b (MathWorks, USA). The indicators of sensitivity, specificity and accuracy of ultrasound and CT were calculated (Table 7). The receiver operating characteristic (ROC) was also plotted, the area under the ROC (Area under the curve, AUC), positive and negative predictive values (PPV and RPV) were calculated. The chi-square test (X2) used for categorical data was calculated and compared to assess the diagnostic efficacy of the two imaging modalities. $P < 0.05$ was considered significant.

Table 7 Analysis of the diagnostic efficiency of instrumental imaging methods

	Ultrasound	CT
Sensitivity	86.4%	95.2%
Specificity	84.9%	95%
Accuracy	85.7%	95.1%

Table 8 The area under the performance curve (AUC) of ultrasound versus CT in the diagnosis of urolithiasis

	AUC	X2	P
Ultrasound	0.6852	0.51	0.4717
CT	0.8632		

Figure 4 - ROC-curves of ultrasound and CT in the diagnosis of urolithiasis

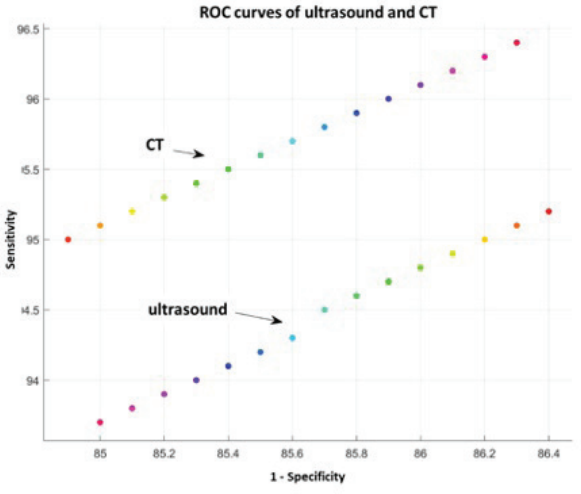

Comparative characteristics of the effectiveness of ultrasound and CT show that CT, as expected, has an advantage over ultrasound in all the above parameters. These data are also confirmed by the results of calculating the ROC curve and the AUC area (Tables 7 and 8, Figure 4).

Discussion

Thus, the results of a complex instrumental examination of the kidney identified 58 calculi in 27 patients out of 78 patients with urolithiasis. At the same time, 28 (48.3%) of the 58 calculi

were identified in the right kidney and 30 (51.7%) in the left kidney. In the upper group of pyramids, 3 (10.7%) calculi were found in the right kidney, 2 (6.7%) calculi in the left kidney. In the middle group of pyramids, 9 (32.2%) and 10 (33.3%) calculi were found in the right and left kidneys, respectively. In the lower group of pyramids of the right and left kidneys, respectively, 8 (28.6%) and 9 (30%) calculi were found. In the pelvis of the right and left kidneys, 5 (17.8%) and 3 (10%) calculi were found and, respectively, the calyx-pelvis complex of the right and left kidneys - 3 (10.7%) and 6 (20%). According to the location of stones in the left kidney - 30 stones and the right kidney - 28, which is 2 more stones. The volume of calculi is noted in the middle group of cups for one calculus and in the lower group of cups for one calculus. 2 times the volume of calculi were found in the calyx-pelvic complex of the left kidney 6 calculi, against 3 calculi of the right kidney.

In addition, the indicators of the diagnostic efficiency of ultrasound and CT methods for detecting calculi in the kidneys were revealed. Thus, the indicators of sensitivity, specificity and accuracy for ultrasound were 86.4%; 84.9%; 85.7%, respectively, and, accordingly, with CT diagnosis, it was 95.2%; 95%; 95.1%, respectively. This is also confirmed by a significant increase in ROC and AUC in CT diagnosis of urolithiasis, with a chi-square value of 0.52. However, according to P = 0.4717, the data did not reveal statistical significance between instrumental methods for diagnosing urolithiasis, which does not exceed 0.05.

Among the limitation of this study it should be noted that it would be better to analyze the effectiveness of studies depending on the body mass index (BMI) of patients, comparison in groups with different BMI, since this factor significantly affects the effectiveness of diagnostics. This issue will be addressed in the further studies and BMI impact on the effectiveness will be calculated.

Patients with urolithiasis require the use of high-tech methods of examination and treatment, both non-invasive and surgical [17,18]. Timely and accurate diagnosis of urolithiasis helps to avoid complications of the disease. Radiation diagnostic methods: ultrasound, X-ray, radionuclide, magnetic resonance allow you to obtain information about the anatomical and functional state of the urinary system; identify developmental anomalies, carry out differential diagnostics with other diseases and conduct dynamic control over treatment [19-21].

Disclosures: There is no conflict of interest for all authors.

Acknowledgements: We thank all patients for their participation in this study. We also acknowledge all our colleagues for their patience, consultation and support.

Funding: None.

References

1. Wallace RB, Wactawski-Wende J, O'Sullivan MJ, Larson JC, Cochrane B, Gass M, Masaki K. Urinary tract stone occurrence in the Women's Health Initiative (WHI) randomized clinical trial of calcium and vitamin D supplements. *Am J Clin Nutr.* 2011;94(1):270-7. https://doi.org/10.3945/ajcn.110.003350.
2. Kadyrov ZA, Istratov VG, Suleymanov SI. Some questions of the etiology and pathogenesis of urolithiasis [in Russian]. *Urologiya*. 2006;5:98-101.
3. Ol'shanskaya EV. Doppler and radiothermometric assessment of renal blood flow in patients with urolithiasis [in Russian, Dis.kand. med.nauk.]. *Moscow*. 2007:137.
4. Dogan HS, Tekgul S. Management of pediatric stone disease. *Curr Urol Rep.* 2007;8(2):163-73. https://doi.org/10.1007/s11934-007-0067-8.
5. Biyani CS, Joyce AD. Urolithiasis in pregnancy. I: pathophysiology, fetal considerations and diagnosis. *BJU Int*. 2002;89(8):811-8; https://doi.org/10.1046/j.1464-410x.2002.02772.x.
6. Worster A, Preyra I, Weaver B, Haines T. The accuracy of noncontrast helical computed tomography versus intravenous pyelography in the diagnosis of suspected acute urolithiasis: a meta-analysis. *Ann Emerg Med*. 2002;40(3):280-6. https://doi.org/10.1067/mem.2002.126170.
7. Andrabi Y, Patino M, Das CJ, Eisner B, Sahani DV, Kambadakone A. Advances in CT imaging for urolithiasis. *Indian J Urol*. 2015;31(3):185-193. https://doi.org/10.4103/0970-1591.156924
8. Villa L, Giusti G, Knoll T, Traxer O. Imaging for Urinary Stones: Update in 2015. *Eur Urol Focus.* 2016;2(2):122-129. https://doi.org/10.1016/j.euf.2015.10.007.
9. Vrtiska TJ, Krambeck AE, McCollough CH, Leng S, Qu M, Yu L, Lieske JC. Imaging evaluation and treatment of nephrolithiasis: an update. Minn Med. 2010;93(8):48-51.
10. Steel R, Poepping TL, Thompson RS, Macaskill C. Origins of the edge shadowing artefact in medical ultrasound imaging. Ultrasound Med Biol. 2004;30(9):1153-62. https://doi.org/10.1016/j.ultrasmedbio.2004.07.014.
11. 11. Chen Y, Li Y, Guo H, Hu Y, Luo L, Yin X, Gu J, Toumoulin C. CT Metal Artifact Reduction Method Based on Improved Image Segmentation and Sinogram In-Painting. *Math Probl Eng*. 2012: 18. https://doi.org/10.1155/2012/786281.
12. Schulze R, Heil U, Gross D, Bruellmann DD, Dranischnikow E, Schwanecke U, Schoemer E. Artefacts in CBCT: a review. *Dentomaxillofac Radiol.* 2011;40(5):265-73. https://doi.org/10.1259/dmfr/30642039.
13. Ahn H, Hernández-Andrade E, Romero R, Ptwardhan M, Goncalves LF, Aurioles-Garibay A, Garcia M, Hassan SS, Yeo L. Mirror artifacts in obstetric ultrasound: case presentation of a ghost twin during the second-trimester ultrasound scan. *Fetal Diagn Ther.* 2013;34(4):248-52. https://doi.org/10.1159/000353702.
14. Sarica K, Erturhan S, Yurtseven C, Yagci F. Effect of potassium citrate therapy on stone recurrence and regrowth after extracorporeal shockwave lithotripsy in children. *J Endourol.* 2006;20(11):875-9. https://doi.org/10.1089/end.2006.20.875.
15. Dvoryakovskiy IV. Possible errors in the recognition of kidney stones by ultrasound [in Russian]. *Rossiyskiy pediatricheskiy zhurnal.* 2017;20(1):53-57.
16. Bandaru RS, Sornes AR, Hermans J, Samset E, D'hooge J. Delay and Standard Deviation Beamforming to Enhance Specular Reflections in Ultrasound Imaging. IEEE Trans Ultrason Ferroelectr Freq Control. 2016;63(12):2057-2068. https://doi.org/10.1109/TUFFC.2016.2613963.

17. Lopatkin NA, Dzeranov NK. Fifteen years of experience in the use of SWL in the treatment of KSD [in Russian]. *Mater. Plenum. Pravleniya Ros.obshchestva urologov, Sochi-Moskva.* 2003;5-25.
18. Dogan HS, Tekgul S. Management of pediatric stone disease. *Curr Urol Rep*. 2007;8(2):163-73. https://doi.org/10.1007/s11934-007-0067-8.
19. Sas DJ, Hulsey TC, Shatat IF, Orak JK. Increasing incidence of kidney stones in children evaluated in the emergency department. *J Pediatr.* 2010;157(1):132-7. https://doi.org/10.1016/j.jpeds.2010.02.004.
20. Shomenko SV, Ukrainets YP. Innovations and advances in the diagnosis and treatment of urolithiasis [in Russian]. *Ukrainskiy nauchno-prakticheskiy zhurnal urologov, andrologov i nefrologov.* 2017;5:44-54.
21. Lebedev DG. Possibilities of dual-energy spiral computed tomography in the analysis of the chemical composition of calculus in urolithiasis [in Russian]. *Luchevaya diagnostika i terapiya.* 2017;3(8):110-111.